

# chapter VII

## Lumbar Paravertebral (Psoas Compartment) Block

### Introduction

When evaluating the efficacy of centrally performed nerve blocks one must think in terms of dermatomes and osteotomes rather than neurotomes.<sup>1</sup> The dermatomal supply of the hip joint, for example, is typically from L4 to as low as S2, while the bony structures of the hip joint are supplied from L3 to S1. Looking at neurotomes, in addition, the anterior obturator nerve, which originates from L2 (amongst others) supplies an articular branch to the hip joint. A wide spread of high-concentration regional anesthetic agent would therefore be required if a lumbar plexus block would be used as sole anesthetic for hip surgery, for example. The same argument holds for knee and ankle surgery. The lumbar plexus block is thus typically used for the management of acute pain rather than for sole anesthetic for lower limb surgery.

Lumbar plexus blocks produce anesthesia of most of the lumbar nerve roots and some of the sacral nerve roots. It therefore produces anesthesia to the lower extremity in the distribution of the femoral nerve, the obturator nerve and the lateral cutaneous nerve of the thigh. If anesthesia to the lower leg or posterior thigh is needed for the procedure, sacral nerve roots block must be added, typically in the form of a sciatic nerve block.<sup>1</sup> The psoas compartment is a relatively large and well-defined compartment and the musculature (the psoas muscle) is a loosely compacted muscle. A large volume of local anesthetic agent is therefore needed to fill this compartment.

Most continuous catheter techniques that developed after the initial attempts of Ansbro in 1946<sup>2</sup> were hampered by inaccurate catheter placement or catheter dislodgement. In order to provide reliable analgesia for lower extremity surgery and prevent readmission due to failed catheter placement, it was

necessary to develop a method to ensure real-time catheter positioning (i.e., during placement). This can now be done immediately rather than hours later when the initial block has worn off for all continuous peripheral nerve blocks, by stimulating the nerves via both the needle through which the catheter is placed and via the catheter itself.<sup>3</sup> This accuracy of catheter placement is combined with a method to secure the catheter so that it does not become dislodged. Although it is probably not always strictly necessary to place the needle and catheter for continuous psoas compartment block with the aid of a nerve stimulator, and loss of resistance to air may also be used successfully, it may give more reliable results if a nerve stimulator and loss-of-resistance to air are used. This author strongly prefers the use of a nerve stimulator for most “single shot” and continuous peripheral nerve blocks.

### Indications

This block is mainly indicated for the management of pain associated with unilateral lower limb surgery. Neuraxial block may well be more effective in producing lower extremity block, but there are patients in whom avoidance of bilateral lower extremity block

or the sympathectomy accompanying neuraxial block is desirable.<sup>1</sup> It may also be used in patients on anticoagulation therapy where neuraxial block is contra-indicated.



**This is a high risk block and careful attention must be given to balancing risks and benefits. Soft indications are lower limb surgery, hernia surgery, knee surgery, etc. High complication rates can therefore be expected when used for these indications. Conversely, hard indications are REVISION (not primary) total hip replacement, pelvic osteotomy and femur osteotomy. Here low complication rates can be expected.**

This is a handy block if proper continuous femoral block cannot be done for technical or, for example, sepsis reasons.

### Equipment

A sheathed insulated 17-gauge Tuohy needle (Arrow International, Reading, PA, USA) and a catheter with an inner steel spring capable of conducting electrical impulses to its distal uncovered “bullet-tip” end—a “stimulating catheter”—are used for the methods described here (Arrow StimuCath®, Arrow International, Reading, PA, USA).

## Anatomy

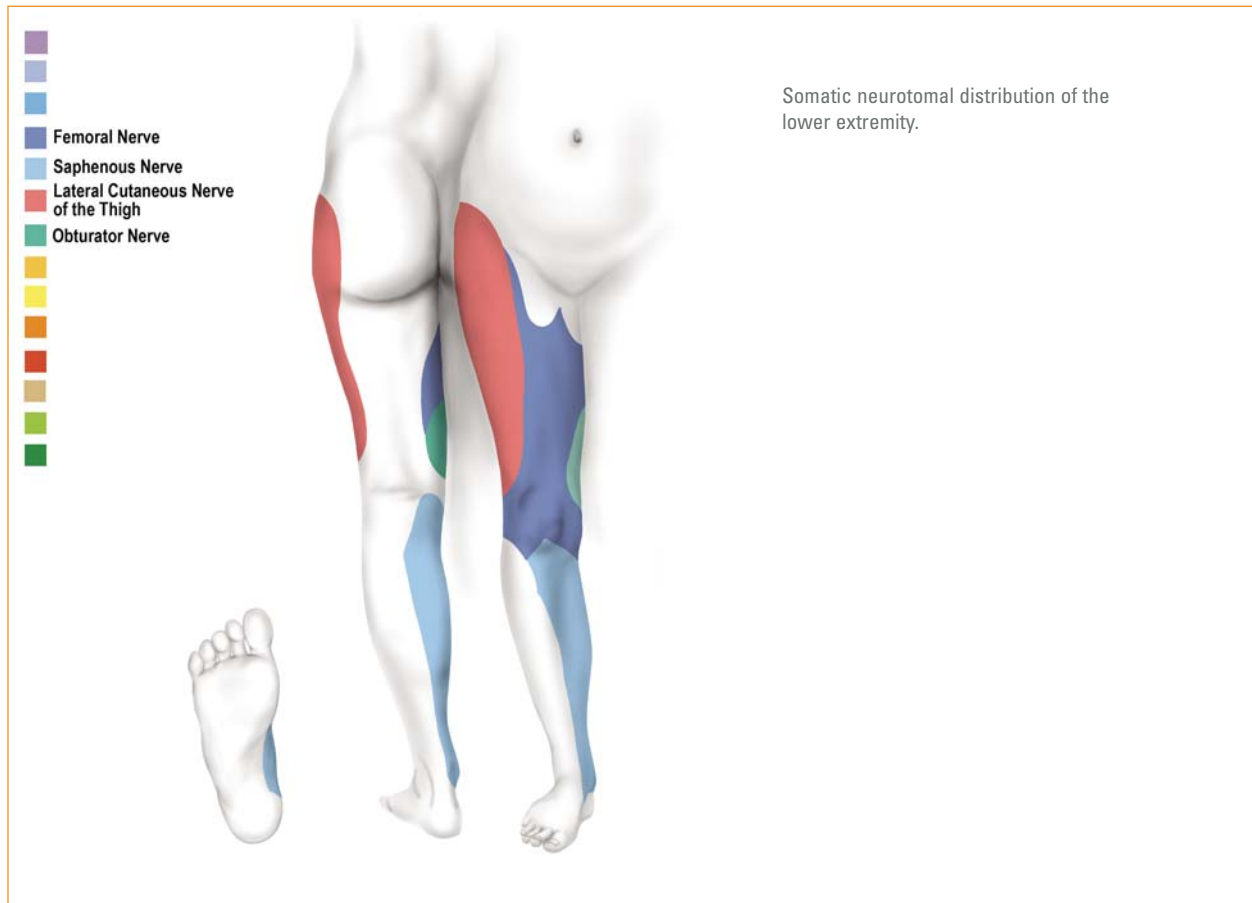
### Applied Anatomy

Due to the multiplicity and divergence of the nerve supply to the joints of the lower extremity, a single nerve block is almost never adequate as the sole anesthetic for lower limb surgery. It is almost always necessary to block more than one major peripheral nerve to the lower extremity. A femoral nerve block, for example, is usually performed in conjunction with a sciatic, and/or obturator, and/or lateral cutaneous nerve of the thigh block. The sensory distribution of the lower extremity nerve supply is outlined in Figure 7.1.<sup>1</sup>

When evaluating the efficacy of more **centrally** performed nerve blocks (as opposed to peripheral nerve blocks) one must think in terms of dermatomes and osteotomes rather than neurotomes.<sup>1</sup> The dermatomal supply of the hip joint, for example, is typically from L4 to as low as S2, while the bony structures of the hip joint are supplied from L3 to S1. Looking at neurotomes, in addition, the anterior obturator nerve, which originates from L2 (amongst others) supplies an articular branch

to the hip joint. A wide spread of high concentration regional anesthetic agent would therefore be required if a lumbar plexus block would be used as sole anesthetic for hip surgery. The same argument holds for knee and ankle surgery. The lumbar plexus block is thus typically used for the management of acute pain rather than for sole anesthetic for lower limb surgery.

Lumbar plexus blocks produce anesthesia of most of the lumbar nerve roots and some of the sacral nerve roots, thus producing anesthesia to the lower extremity in the distribution of the femoral nerve, the obturator nerve and the lateral cutaneous nerve of the thigh. If anesthesia to the lower leg or posterior thigh is needed for the procedure, sacral nerve roots block must be added, typically in the form of a sciatic nerve block.<sup>1</sup> The psoas compartment is a relatively large and well-defined compartment and the musculature (the psoas muscle) is a loosely compacted muscle. A large volume of local anesthetic agent is therefore needed to fill this compartment.



**Figure 7.1**

The dorsal divisions of the anterior rami of the second, third and fourth lumbar nerves form the femoral nerve (Figure 7.1).<sup>4</sup> The iliohypogastric, ilioinguinal and genitofemoral nerves are formed from the dorsal divisions of the twelfth thoracic nerve and that of the first and second lumbar nerves. The femoral nerve emerges from the pelvis beneath the inguinal

ligament just lateral to and approximately 0.5–1 cm posterior to the femoral artery. This relationship to the femoral artery exists near the inguinal ligament, not after the nerve enters the thigh. As the nerve passes into the thigh, it divides into an anterior and a posterior division.

The anterior division gives off anterior cutaneous and muscular branches to the sartorius muscle. The posterior division gives off the saphenous nerve, which is the largest cutaneous branch of the femoral nerve. It also gives off muscular branches and articular branches.

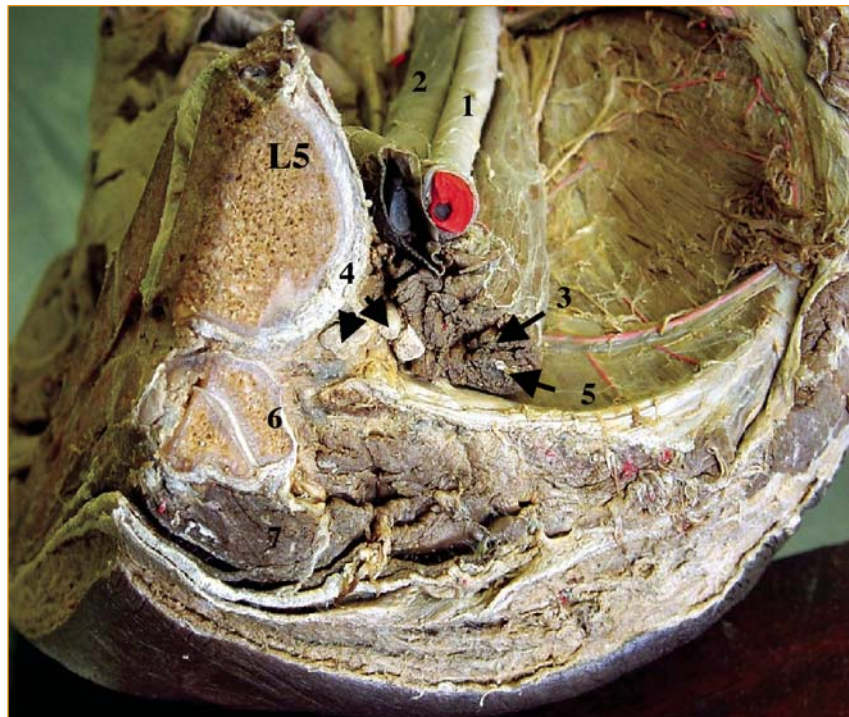The dorsal divisions of the anterior rami of the second, third and fourth lumbar nerves also form the lateral cutaneous nerve of the thigh, the obturator nerve and the accessory obturator nerve. The obturator nerves supply the obturator externus and adductor muscles of the thigh, the articulations of the hip and knee joints, and occasionally the integument of the thigh and leg. It descends through the inner fibres of the psoas muscle, and emerges from the inner border near the brim of the pelvis. It then runs along the lateral wall of the pelvis, above the obturator vessels, to the upper part of the obturator foramen, where it enters the thigh and divides into an anterior and posterior branch, separated by some of the fibres of the obturator externus muscle and lower down by the adductor brevis muscle.

The lateral cutaneous nerve of the thigh (sometimes referred to as the external cutaneous nerve) emerges from the outer border of the psoas muscle about in its middle, and crosses the iliacus muscle obliquely, towards the anterior superior spine of the ilium. It passes under the inguinal ligament and over the sartorius muscle into the thigh, where it divides into anterior and posterior branches. As the name implies, it is responsible for sensation on the lateral aspect of the thigh.

The union of the anterior rami of the fourth and fifth lumbar nerves and the first, second and third sacral nerves forms the sciatic nerve (Figure 7.1).<sup>4</sup> It is the largest nerve in the body and in practical (regional anesthesia) terms a group of nerves rather than a single nerve. The sciatic nerve passes out of the pelvis through the greater sciatic notch and descends between the tuberosity of the ischium and the greater trochanter of the femur along the posterior aspect of the leg. It divides into the tibial and common peroneal nerves, usually 7–9 cm from the popliteal groove.

The Common Iliac Artery (1) (Figure 7.2) and Common Iliac Vein (2) are situated anterior to the psoas muscle (3), which is inside a fascial sheath, the psoas compartment. The roots of

the lumbar plexus (4) are also in this compartment and are situated postero-medial to the psoas muscle (3). The genitofemoral nerve (5) is situated in the body of the psoas muscle.



- (1) Common iliac artery
- (2) Common iliac vein
- (3) psoas muscle
- (4) Dorsal divisions of roots of lumbar plexus
- (5) Genitofemoral nerve
- (6) the pars intervertebralis of the 5th lumbar vertebra and also shows the facet (zygapophyseal) joint.
- (7) Multifidus muscle
- (L5) Body of the 5th lumbar vertebra

**Figure 7.2**

### Anatomic landmarks (see also needle placement below)

There are basically four approaches to the lumbar plexus block. All four are useful and will briefly be described here. The fourth (paravertebral) approach is the approach favored by the present author.

## Technique

### Patient position

The patient lies in the lateral decubitus position with the thighs flexed and the operative extremity uppermost.

### Needle Placement

After liberal skin and subcutaneous tissue infiltration of local anesthetic agent, the needle enters the skin in one of four positions.

#### Approach 1: (according to Brown<sup>1</sup>)

A line is drawn between the two iliac crests (Tuffier's line). The vertebral dorsal spine palpable on this line is usually the fourth lumbar spine. The midline is marked on this spine, and a second line is drawn 5 cm lateral and parallel to the midline. A mark, which identifies the needle entry site, is made 3 cm caudal to Tuffier's line on the second line and contact by the needle with the transverse process of the fifth lumbar vertebra is sought.

#### Approach 2 (according to Solanski<sup>5</sup>)

The spinous processes of the third, fourth and fifth lumbar vertebrae are identified and marked. Similarly the posterior superior iliac crest is identified and marked and a line that goes through this point is drawn parallel to the midline. The highest point of the iliac crest is then identified and marked and a line that joins this point with the dorsal spine of L5 is drawn. Where this line crosses the line extended cephalad from the posterior superior iliac crest is the point of needle entry. Again, contact with the transverse process of L5 is sought.

#### Approach 3 (according to Bridenbaugh and Wedel<sup>5</sup>)

Skin wheals are raised opposite the cephalad aspect of the spinous process of L4 or L5 on a line 3 to 4 cm laterally from, and parallel to, the midline of the back. The cephalad aspect of the spinous processes of the lumbar vertebrae are on the same horizontal line as the caudad aspect of the transverse processes of the same vertebra. Contact with the transverse process of any lumbar vertebra is sought, depending on the level at which the lumbar plexus block is performed.

In all three of the above approaches the needle enters perpendicular to the skin in all plains and, after contact with the transverse process of the vertebra, the needle tip is caudally “walked off” the transverse process to enter the psoas compartment.

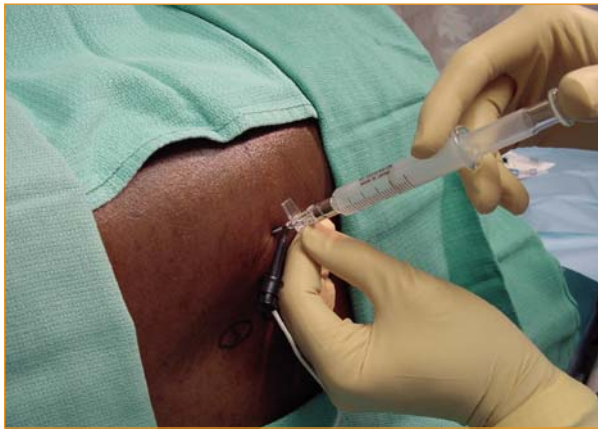#### Approach 4: (paravertebral approach)

A line extended horizontally through the middle of the dorsal spine of the fourth lumbar vertebra goes midway between the transverse processes of the fourth and fifth lumbar vertebrae. The midpoint of the dorsal spine of the fourth vertebra is used as the first landmark and is extended laterally. (If a higher block is required, higher up spinous processes can be used). Needle entry is 3–4 cm lateral to the midline (or two-thirds the distance from the midline to a line parallel to the midline through the superior posterior iliac spine—the approach described by Capdevila). The needle is aimed antero-medially such that contact with the pars intervertebralis, between the two transverse processes, of the vertebrae is sought. “Walking off” this bony structure infero-laterally brings the needle into the vicinity of the intervertebral foramen. Definitely identifying bone gives a clear indication of depth.

#### For all four approaches:

- > The insulated Tuohy needle is attached to the peripheral nerve stimulator with the current set at 1–3 mA and a pulse width of 200–300  $\mu$ s. (It is not necessary to use shorter pulse widths, but if it is used, it is recommended to use it all the time in order). The needle is advanced until contact with the transverse process or pars intervertebralis of the appropriate vertebra is made.
- > Aim the bevel of the needle in the direction in which the catheter is intended to go.
- > At this point, the needle stylet should be removed and a syringe (loss-of-resistance device) containing 2–3 ml of air attached to the needle (Figure 7.3).
- > The needle is then caudally “walked off” of the transverse process (or laterally off the pars intervertebralis) and slowly advanced anteriorly.
- > When the needle enters the lumbar paravertebral space (psoas compartment), there will be a sudden loss of resistance to air followed immediately by muscle twitches of the quadriceps muscles of the ipsilateral leg due to stimulation of the lumbar plexus. The needle should be stabilized in this position. (In some instances, especially in young people, muscle twitches

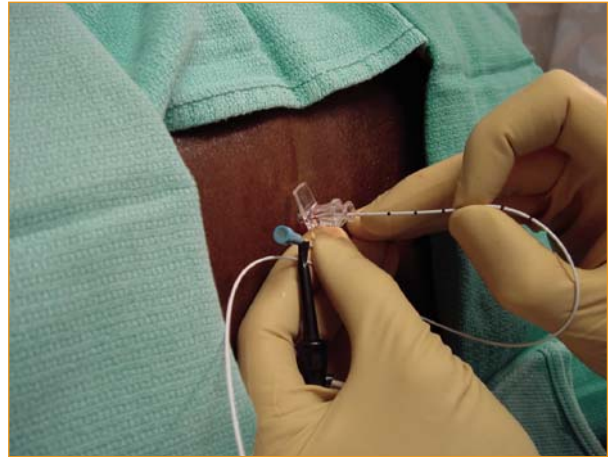
do not occur but the patient will report light “electrical shocks” down the leg. This is because, at this level, the nerve roots may have already split into anterior motor fibers and posterior sensory fibers and, since the nerve stimulation is from posterior, this will cause sensory stimulation only.)



**Figure 7.3—Needle placement**

#### Catheter placement

- > The nerve stimulator clip is now removed from the needle and attached to the proximal end of the stimulating catheter (Figure 7.4). Introduce the stimulating catheter into the needle.



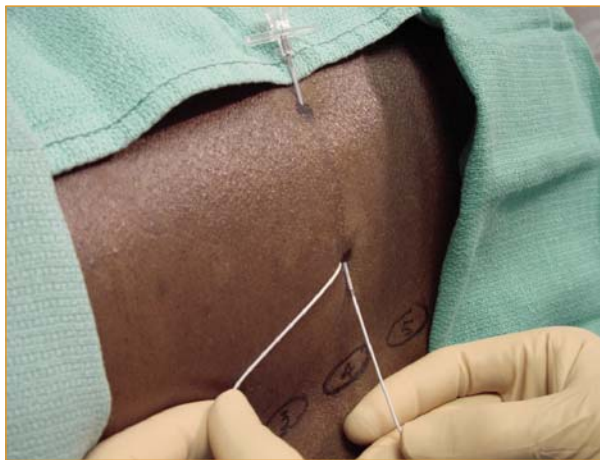
**Figure 7.4—Catheter placement**

- > The muscle twitches should begin again and should be unchanged. The catheter is then gradually advanced beyond the tip of the needle for a distance of approximately 3–5 cm. The muscle twitches should continue unchanged over the entire distance of the catheter advancement.
- > If stimulation ceases during catheter advancement, the catheter should be carefully withdrawn to inside the shaft of the needle, the needle position changed in rotation, angulation or depth until the catheter can be easily advanced with unchanged muscle twitches throughout the procedure.
- > The catheter is now correctly placed near the lumbar plexus but will most likely dislodge over time unless secured.

(A non-stimulating standard soft epidural catheter may be advanced through the needle after loss of resistance to air and nerve stimulation *via* the needle and catheter omitted if muscle twitches are undesirable or painful. A lower success rate may have to be accepted if this is done, but this notion has not yet been evaluated by formal research.)

#### Tunneling to secure catheter

Penetrate the skin with the inner steel stylet of the needle 1–3 mm from the catheter entry site and advance the stylet subcutaneously in a lateral direction to exit the skin 8–10 cm laterally (Figure 7.5). Proceed further as outlined in chapter 1.



**Figure 7.5—Tunneling**

## Drugs

### Initial bolus injection

The author uses 0.5ml/kg ropivacaine (0.5–0.75%) or bupivacaine (0.5%) as a bolus injection for intra- and post-operative analgesia if the block is combined with general anesthesia. If it is used as sole anesthetic, 20–40 ml is usually required. Care must then be taken to block the sciatic nerve separately if required.

### Continuous Infusion

Breakthrough pain is rare and patient satisfaction high in patients discharged from hospital with disposable elastometric infusion pumps delivering 5 ml/hr of 0.2% ropivacaine or 0.25% bupivacaine. Patient-controlled injection can be used with satisfactory results.<sup>6</sup>

### Sedation for placing block

Very little or no sedation is typically required for this block. Based on a study of sedation for retrobulbar block,<sup>7</sup> this author uses midazolam 10–50 µg/kg combined with remifentanyl 0.3–0.5 µg/kg or alfentanil 5–10 µg/kg given as an intravenous bolus 1 minute before the placement of the block. The remifentanyl injection can be repeated when necessary if painful conditions such as fractures are present.

Blocks are usually performed in non-anesthetized patients, but under certain circumstances they may be performed in anesthetized patients. These circumstances include situations such as if the patient is a child, when very painful conditions, for example, fractures, are present or when the patient is very anxious. The skin and subcutaneous tissue should always be properly anesthetized for blocks as well as for the intended tunneling path of the catheter.

**Special precautions:**

- > The catheter should always be withdrawn entirely into the needle before the needle is repositioned. Catheter withdrawal should be done carefully to prevent damage to the catheter.
- > The presence of significant paresthesia during catheter advancement should be carefully evaluated before advancement of the catheter.
- > Be suspicious of sub-perineural needle or catheter placement if brisk muscle twitches are present with nerve stimulator settings less than 0.2 mA (except in children).
- > Since an indwelling catheter is left in situ for some time, formal sterile procedures are necessary. The entry site of the catheter should be inspected daily for early signs of infection.
- > Sensation should be allowed to return to the limb before the catheter is removed. Catheters should never be cut while being removed. If the surgical pain is still intolerable, a bolus of the local anesthetic agent should be injected and the infusion initiated again. If surgical pain is tolerable or manageable with simple analgesics, the catheter may be removed by gently pulling on it in the direction of the tunneling or by removing the part distal to the skin bridge first. Radiating pain experienced during removal may indicate that the catheter has curled around a nerve root. Surgical removal of catheters has never been reported to be necessary but should probably be considered if radiating pain persists during attempted removal. The skin bridge makes removal easier.
- > Because the entire arm is likely to be insensitive for the duration of the continuous block, the peroneal nerve at the level below the knee should always be protected.

## References

- <sup>1</sup> Brown DL. Psoas compartment block. In: Brown DL, ed. *Atlas of Regional Anesthesia*. 2nd ed. Philadelphia, PA: W.B. Saunders Company; 1999: 88–91.
- <sup>2</sup> Ansbro P. A method of continuous brachial plexus block. *American Journal of Surgery* 1946; 121: 716–722.
- <sup>3</sup> Boezaart AP, de Beer JF, du Toit C, van Rooyen K. A new technique of continuous interscalene nerve block. *Canadian Journal of Anesthesia* 1999; 46(3): 275–281.
- <sup>4</sup> Moore DC. *Regional Block*. Fourth Edition. Springfield IL, Charles C Thomas Publishers; 1967: 276–277.
- <sup>5</sup> Solanski D. Posterior lumbar plexus (psoas) block. In: Chelly JE, ed. *Peripheral nerve blocks: A color atlas*. Philadelphia, PA: Lippincott Williams and Wilkins; 1999: 90–92.
- <sup>6</sup> Bridenbaugh PO, Wedel DJ. The lower extremity: Somatic blockade. In: Cousins MJ, Bridenbaugh PO, Eds. *Neural Blockade: In Clinical anesthesia and management of pain*. Philadelphia, PA: Lippincott-Raven; 1998: 374–376.
- <sup>7</sup> Borgeat A, Schäppi B, Biasca N, Gerber C. Patient-controlled analgesia after major shoulder surgery: Patient-controlled interscalene analgesia versus patient-controlled analgesia. *Anesthesiology* 1997; 87: 1343–1347.
- <sup>8</sup> Boezaart AP, Berry AR, Nell ML, van Dyk AL. A comparison of propofol and remifentanyl for sedation and limitation of movement during peri-retrobulbar block. *Journal of Clinical Anesthesia* 2001; 13: 422–426.