

# chapter V

## Continuous Femoral Nerve Block

### Introduction

Due to the multiplicity and divergence of the nerve supply to the joints of the lower extremity, a femoral nerve block per se is almost never adequate as the sole anesthetic for lower limb surgery. It is almost always necessary to block the other three major peripheral nerves to the lower extremity as well. A femoral nerve block is therefore usually performed in conjunction with a sciatic block for foot and ankle surgery. It may be sufficient on its own for anterior knee surgery such as ACL repair and total knee replacement.

The sensory distribution of the femoral nerve supply is outlined in Figure 5.1.<sup>1</sup> The anterior approach to the femoral nerve is similar for “single injection” or continuous nerve blocks. This communication will outline the technique for continuous femoral nerve block only. For “single injection” block a Arrow Quick Flash® Catheter needle is typically used and the local

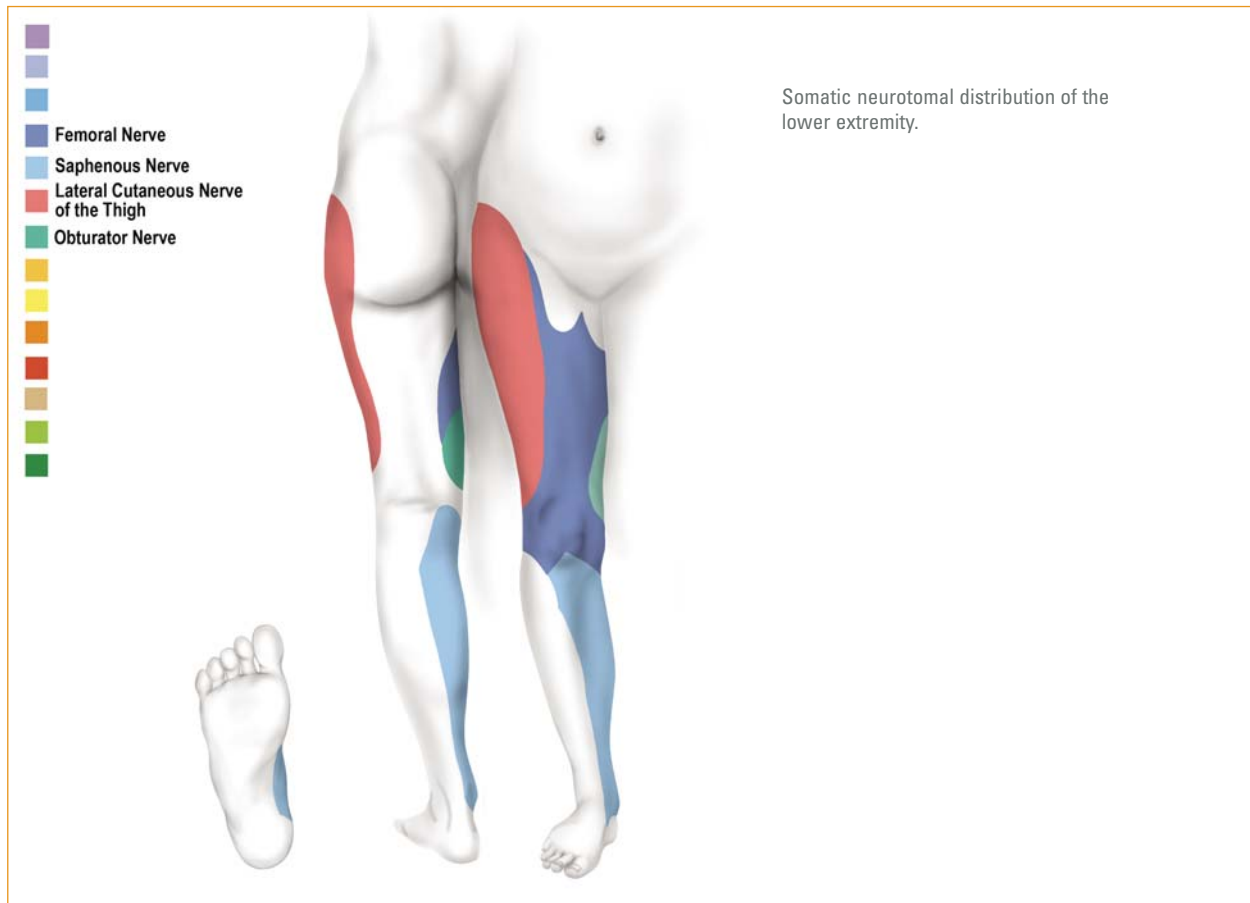
anesthetic agent is injected after location of the nerve with the nerve stimulator set at 0.4–0.6 mA and 200–300  $\mu$ s.

Most continuous catheter techniques that were developed after the initial attempts of Ansbro in 1946<sup>2</sup> were hampered by inaccurate catheter placement or catheter dislodgement. In order to provide reliable analgesia for lower extremity surgery and prevent readmission due to failed catheter placement, it was necessary to develop a method to ensure real-time catheter positioning (i.e., during placement). This can now be done at insertion with all continuous peripheral nerve blocks (rather than hours later when the initial block has worn off), by stimulating the nerves *via* both the needle through which the catheter is placed and *via* the catheter itself.<sup>3</sup> This accuracy of catheter placement is combined with a method to secure the catheter that prevents dislodgment.

### Indications

The femoral nerve block is mainly indicated for the pain control associated with unilateral anterior knee surgery. It is important to note that the posterior obturator nerve gives off an articular branch that supplies the posterior aspect of the knee and this nerve may be responsible for the pain experienced in the posterior aspect of the knee following knee surgery despite an effective femoral nerve block. It was originally thought that this pain was due to the absence of a sciatic nerve block, but work done by the Virginia Mason group<sup>4</sup> disputed this notion. Allen and co-workers demonstrated that there was no difference in post-operative pain if a sciatic nerve block was done in conjunction with a

femoral nerve block. It is, however, necessary to perform a sciatic nerve block additionally if surgery distal or posterior to the knee joint (for example posterior cruciate ligament reconstruction) is done. It is often necessary to block the obturator and/or sciatic nerve separately in addition to the femoral nerve after total knee replacement surgery. The pain experienced in the posterior aspect of the knee is often short-lived and effectively controlled with “single injection” blocks. Continuous femoral nerve blocks have been demonstrated to improve the outcome of total knee arthroplasty.<sup>5</sup> Outcome with continuous femoral nerve block was better than “single shot” femoral block and continuous epidural anesthesia.

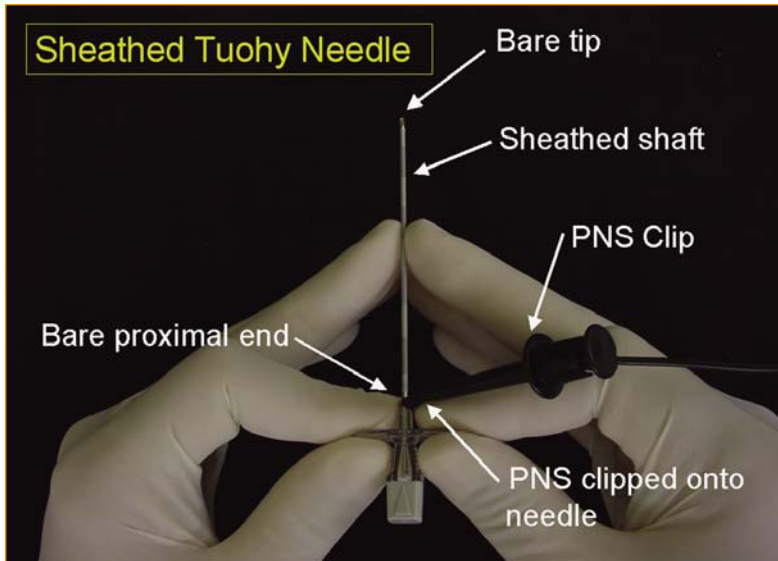


**Figure 5.1**

### Equipment

A sheathed insulated 17-gauge Tuohy needle (Arrow International, Reading, PA, USA) (Figure 5.2a) and a catheter with an inner steel spring capable of conducting electrical

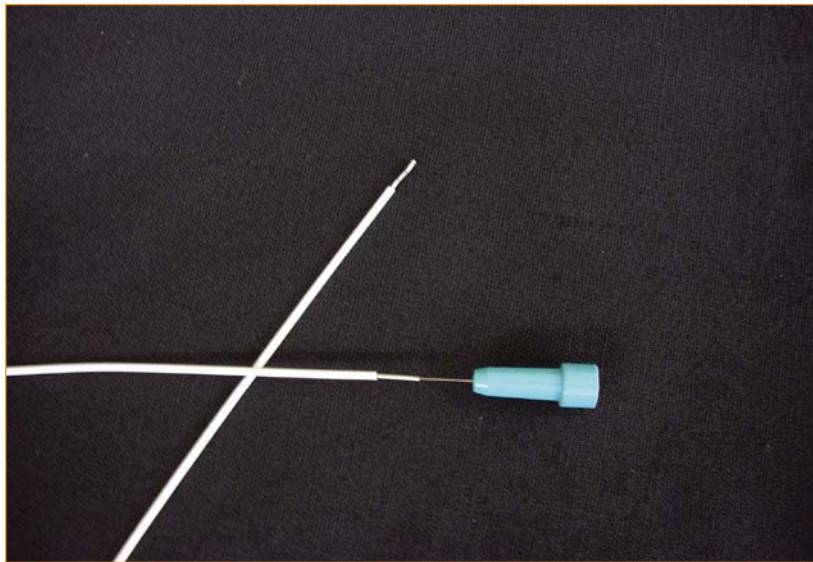
impulses to its distal uncovered “bullet-tip” end—a “stimulating catheter” (Figure 5.2b)—are used in the methods described here (Arrow StimuCath®, Arrow International, Reading, PA, USA).



The StimuCath needle is an insulated Tuohy needle with a bare tip and a bare proximal area.

PNS = Peripheral Nerve Stimulator.

**Figure 5.2a—StimuCath needle**



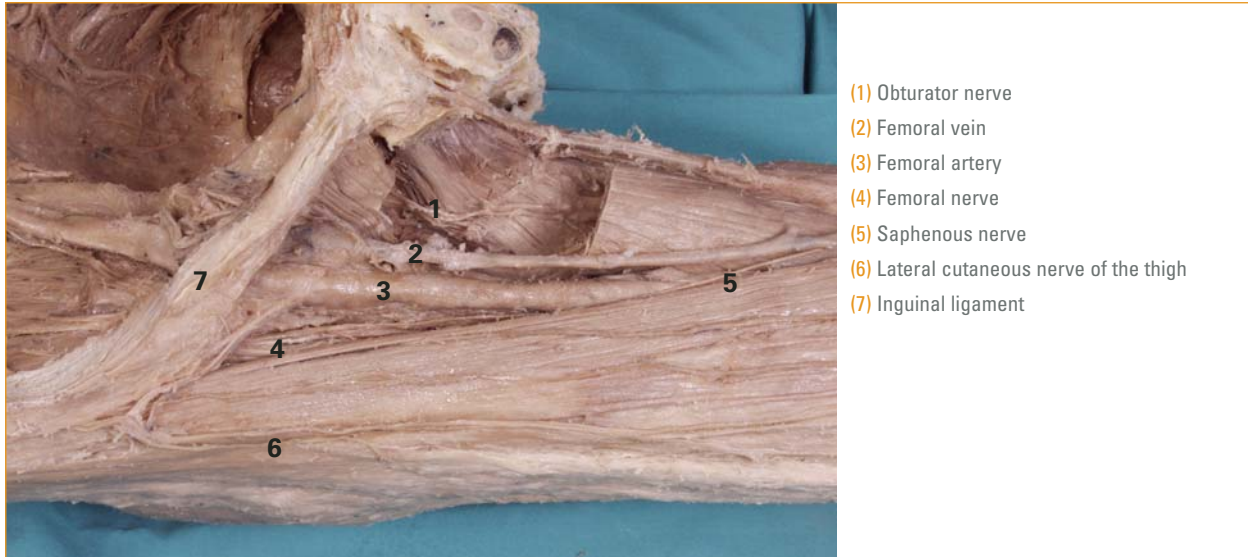The StimuCath catheter has an inner spring reinforcement, which is electrically conductive and continues from its proximal to its distal bare end of the catheter.

**Figure 5.2b—StimuCath catheter**

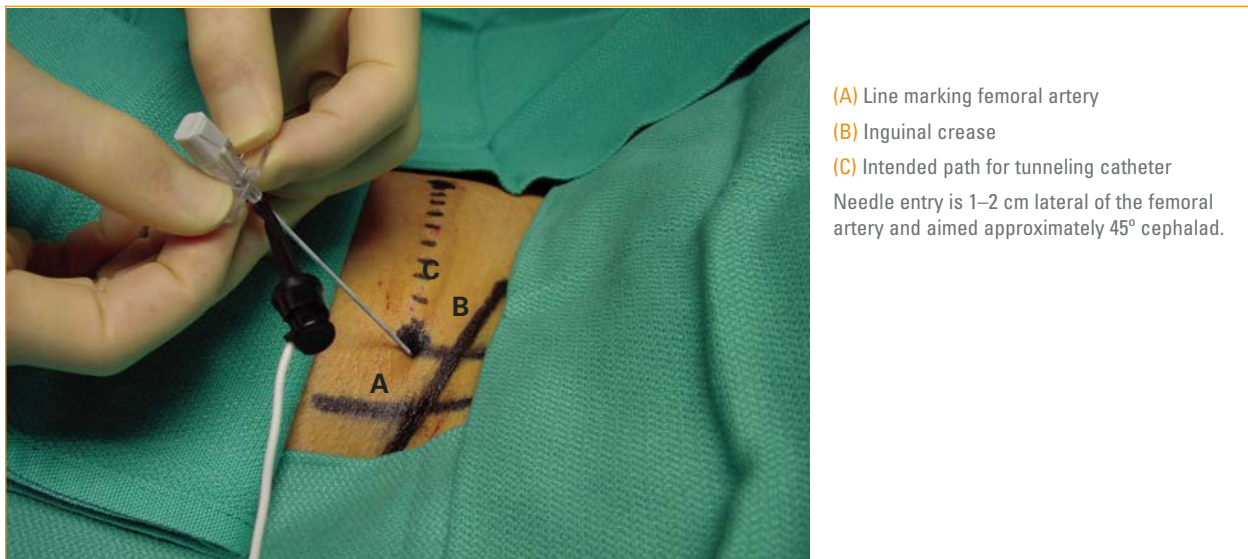
## Anatomy

The femoral nerve is situated lateral to the femoral artery and is deep to the iliaca fascia, which in turn is deep to the fascia lata. The femoral artery and vein, again, is in a separate

fascia compartment (Figure 5.3). The femoral nerve is one nerve bundle near the inguinal crease, but a short distance more distally; it divides into its seven branches.



**Figure 5.3—Anatomy**



**Figure 5.4—Anatomical landmarks and needle placement**

### Anatomic landmarks

See Figure 5.4. Identify and mark the femoral artery in the groin. The femoral nerve is situated 1–2 cm lateral to the femoral artery.

## Technique

### Patient position

The patient lies supine with a clear view of the patella.

### Needle Placement

After generous skin and subcutaneous tissue infiltration of local anesthetic agent (**beware not to block the femoral nerve in the process!**), the needle is inserted aiming approximately 45° cephalad (Figure 5.4). The point of needle entry is just inferior to the inguinal crease. The nerve stimulator is clipped to the proximal bare area of the needle and two definite “pops” are felt when the needle penetrates first the fascia lata and then the iliaca fascia. It is very important to penetrate both these layers of fascia, since the electrical current may well cross the fascia layer and cause muscle twitching, but the local anesthetic agent will not cross the fascia layer if deposited superficial to it. This is a common mistake when performing femoral nerve blocks.

In our experience femoral blocks are predictably successful if the needle is placed deep to the fascia iliaca. Using a nerve stimulator, this will be the case when brisk twitches of the quadriceps muscles are evoked that move the patella while being able to dial the nerve stimulator output down to between 0.3 and 0.6 mA at a pulse width of 200–300  $\mu$ s.

Another common mistake is to stimulate the nerve to the sartorius muscle, which is situated superficial to the fascia iliaca. The local anesthetic agent will then not reach the femoral nerve. Aim the bevel of the needle in the direction in which the catheter is intended to go—cephalad in this instance.

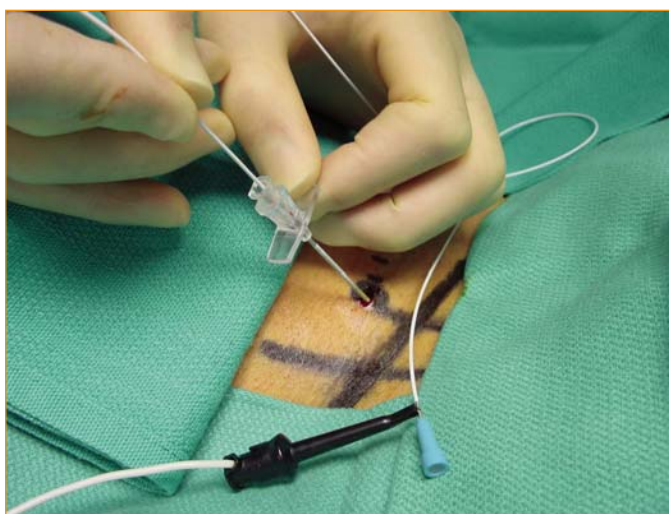
### Catheter placement

- > The nerve stimulator clip is now removed from the needle and attached to the proximal end of the stimulating catheter (Figure 5.5).
- > Introduce the stimulating catheter into the needle.
- > The muscle twitches should resume again and should be unchanged in character and intensity. The catheter is then gradually advanced beyond the tip of the needle for a distance of approximately 3–5 cm.

The muscle twitches (patella movement) should continue unchanged over the entire distance of the catheter advancement.

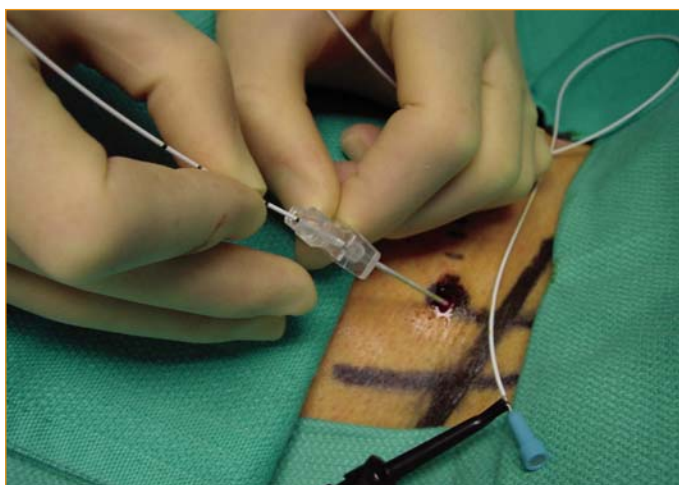
- > If stimulation ceases during catheter advancement, the catheter should be carefully withdrawn to inside the shaft of the needle,

the needle position changed by a combination of rotation (Figure 5.6), angulation or depth adjustment until the catheter advances easily while the muscle twitches are maintained unchanged throughout.



The needle is held steady; the nerve stimulator is now clipped to the proximal end of the catheter and the catheter is advanced through the needle. There should be no change in the quality of the muscle (quadriceps) twitches. Be sure that the same muscles are twitching at the same intensity.

**Figure 5.5—Catheter placement**



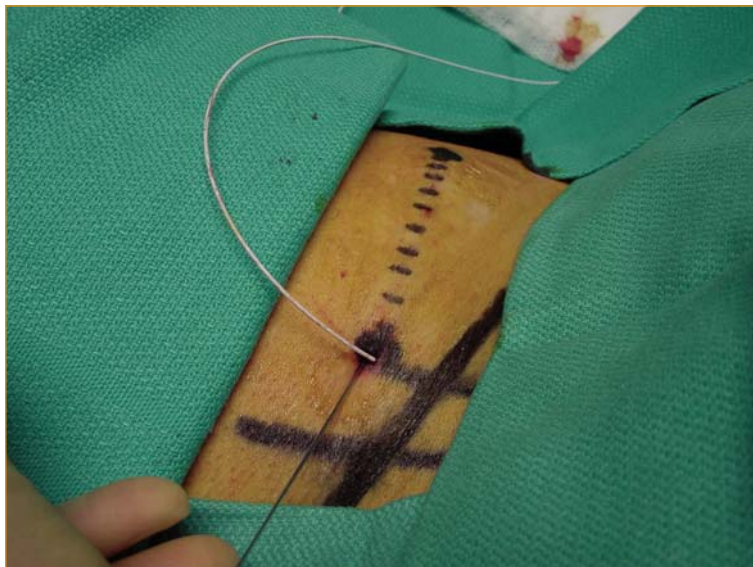
If, during advancement of the catheter, the muscle twitches disappear or change in any way, withdraw the catheter carefully back to inside the needle shaft, make an adjustment to the needle (rotation in this instance) and advance the catheter again. Repeat this maneuver until the twitches remain unchanged throughout the procedure.

**Figure 5.6—Catheter placement**

- > The catheter is now correctly placed near the femoral nerve but will most likely dislodge over time unless secured.

#### Tunneling to secure catheter

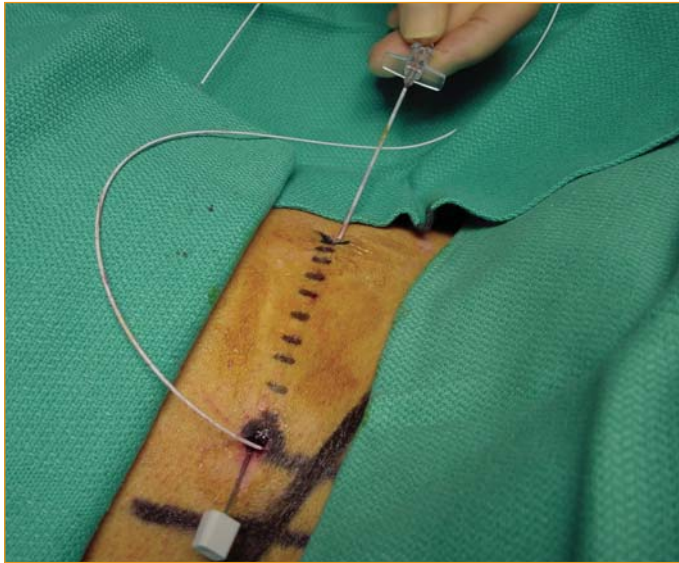
- > Penetrate the skin with the inner steel stylet of the needle 1–3 mm from the catheter entry site and advance the stylet subcutaneously in a lateral direction to exit the skin 8–10 cm laterally (Figure 5.7).



Insert the inner stylet of the needle 2–3 mm from the catheter exit wound and advance subcutaneously to exit the skin 6–10 cm laterally.

**Figure 5.7—Tunneling**

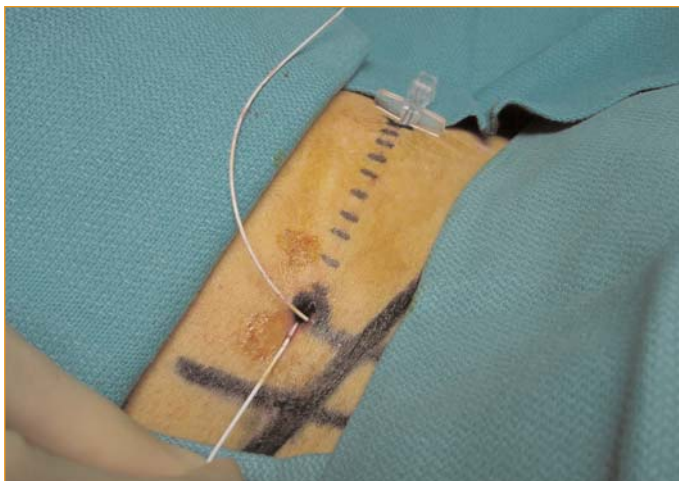
- > “Rail-road” the needle over the stylet (Figure 5.8).



Insert the inner stylet of the needle 3–5 mm from the catheter exit site and advance subcutaneously to exit the skin approximately 8–10 cm laterally and “rail-road” the needle retrogradely back over the stylet. See text.

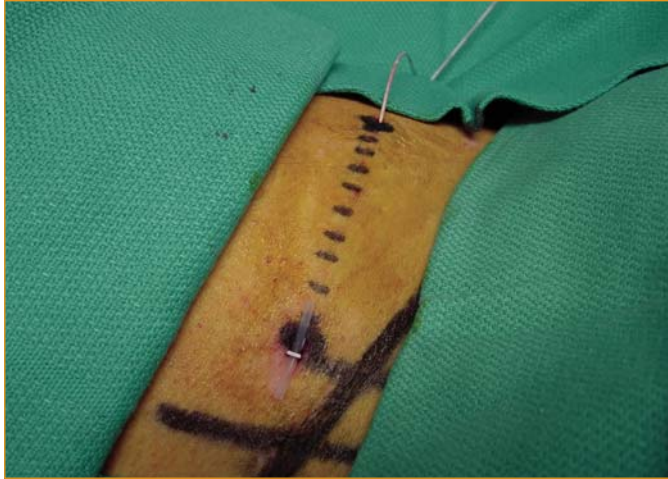**Figure 5.8—Tunneling**

- > Remove the stylet and feed the catheter retrogradely through the needle (Figure 5.9). After passage of the catheter, remove the needle (Figure 5.9) and observe the skin bridge (Figure 5.10).



Remove the stylet from the needle and feed the proximal end of the catheter through the needle.

**Figure 5.9—Tunneling**



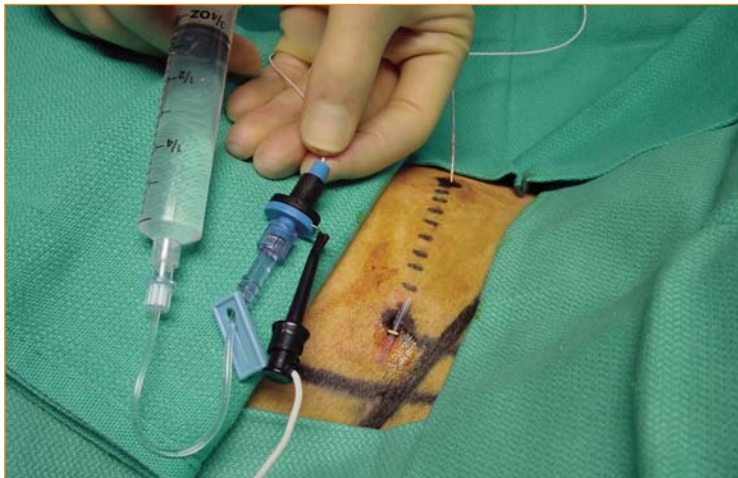Remove the needle and secure the catheter with sterile dressings. Observe the skin bridge. If the skin bridge is undesirable, allow the needle to exit through the same hole in the skin as the catheter. Be careful not to damage the catheter with the needle.

**Figure 5.10—Tunneling**

#### Final Stimulation Test

- > Apply the SnapLock™ (Arrow International, Reading, PA, USA) device onto the proximal end of the catheter.
- > Attach the nerve stimulator to the SnapLock™

and perform a final stimulation test—sometimes referred to as the “Raj test” (Figure 5.11). The muscle twitches disappear almost immediately after injection of the first few milliliters of local anesthetics.



Inject local anesthetic agent while stimulating the nerve *via* the SnapLock (Arrow Intl, Reading, PA, USA) now attached to the catheter. Set the nerve stimulator to the lowest output that will still cause brisk muscle twitches and note that the twitches stop immediately once the injection is started. This provides additional confirmation that the block will be successful and is sometimes referred to as the “Raj test.” Inject the rest of the bolus dose in 5 ml increments.

**Figure 5.11—Final stimulation test (“Raj test”)**

## Drugs

### Initial bolus injection

The authors use 15–40 ml ropivacaine (0.5–0.75%) or bupivacaine (0.5%) as a bolus injection for intra- and post-operative analgesia if the block is combined with general anesthesia. If it is used as sole anesthetic (usually in combination with a sciatic nerve block), 0.5 ml/kg is usually required.

### Continuous Infusion

Breakthrough pain is rare and patient satisfaction high in patients when an infusion of 5 ml/hr of 0.2% ropivacaine or 0.25% bupivacaine is used. Patient-controlled injection boluses of 5–10 ml and a lockout time of 30–60 minutes will provide satisfactory results.<sup>6</sup>

### Sedation for placing block

Very little or no sedation is typically required for this block. Based on a study of sedation for retrobulbar block,<sup>7</sup> we use midazolam 10–50 µg/kg combined with remifentanyl 0.3–0.5 µg/kg or alfentanil 5–10 Mg/kg given as an intravenous bolus 1 minute before the placement of the block. The remifentanyl injection can be repeated when necessary if painful conditions such as fractures are present. Alfentanil or fentanyl is also appropriate

alternatives in this situation.

Blocks are usually performed in non-anesthetized patients, but under certain circumstances they may be performed in anesthetized patients. Examples include children, very painful conditions such as fractures, or very anxious patients. The skin and subcutaneous tissue should always be properly anesthetized for blocks as well as for the intended tunneling path of the catheter.

### Special precautions:

- The catheter should always be withdrawn entirely into the needle before the needle is repositioned. Catheter withdrawal should be done carefully to prevent damage to the catheter.
- The presence of significant paresthesia during catheter advancement should be carefully evaluated before advancement of the catheter.
- Be suspicious of sub-perineural needle or catheter placement if brisk muscle twitches are present with nerve stimulator settings less than 0.2 mA (except in children).
- Since an indwelling catheter is left in situ for some time, formal sterile procedures are necessary. The entry site of the catheter

should be inspected daily for early signs of infection.

- > Sensation should be allowed to return to the limb before the catheter is removed. Catheters should never be cut while being removed. If the surgical pain is still intolerable, a bolus of the local anesthetic agent should be injected and the infusion initiated again. If surgical pain is tolerable or manageable with simple analgesics, the catheter may be removed by gently pulling on it in the direction of the tunneling or by removing the part distal to the skin bridge first. Radiating pain experienced during removal may indicate that the catheter has curled around a nerve root. Surgical removal of catheters has never been reported to be necessary but should

probably be considered if radiating pain persists during attempted removal. The skin bridge makes removal easier.

### References

- <sup>1</sup> Brown DL. *Atlas of Regional Anesthesia*. 2nd ed. Philadelphia, PA: W.B. Saunders Company; 1999.
- <sup>2</sup> Ansbro P. A method of continuous brachial plexus block. *American Journal of Surgery* 1946; 121: 716–722.
- <sup>3</sup> Boezaart AP, de Beer JF, du Toit C, van Rooyen K. A new technique of continuous interscalene nerve block. *Canadian Journal of Anesthesia* 1999; 46(3): 275–281.
- <sup>4</sup> Allen HW, Lui SS, Ware PD, Nairn CS, Owens BD. Peripheral nerve blocks improve analgesia after total knee replacement surgery. *Anesth Analg* 1998; 93: 93–97.
- <sup>5</sup> Capdevilla X, Barthelet Y, Biboulet P, Ryckwaert Y, et al. Effects of perioperative technique on surgical outcome and duration of rehabilitation after major knee surgery. *Anesthesiology* 1999; 91: 8–15.
- <sup>6</sup> Borgeat A, Schäppi B, Biasca N, Gerber C. Patient-controlled analgesia after major shoulder surgery: Patient-controlled interscalene analgesia versus patient-controlled analgesia. *Anesthesiology* 1997; 87: 1343–1347.
- <sup>7</sup> Boezaart AP, Berry AR, Nell ML, van Dyk AL. A comparison of propofol and remifentanyl for sedation and limitation of movement during peri-retrobulbar block. *Journal of Clinical Anesthesia* 2001; 13: 422–426.